

# Chemical and Biological Effects of Digoxin on Albino Rat Fetuses

Abd El Wahab El Ghareeb<sup>1\*</sup>, Said Abd El Rahman Mostafa<sup>2</sup>, Heba Ali<sup>1</sup>, Talal Jubayr AL-harhi<sup>3</sup>

<sup>1</sup>Zoology Department, Faculty of Science  
Cairo University, Egypt.

<sup>2</sup>Chemistry Department, Faculty of Science  
Cairo University, Egypt

<sup>3</sup>Zoology Department, Faculty of Science  
Taif University, Saudi Arabia

\*Corresponding author's email: drelghareeb [AT] yahoo.com

---

**ABSTRACT---** *Digoxin is used in the treatment of chronic heart failure and/or atrial fibrillation and flutter (irregular heart rhythms caused by an electrical problem in the upper chambers of the heart). The aim of this study was to evaluate the teratogenic effects of Digoxin on pregnant rats and their fetuses. Pregnant albino rats (*Rattus norvegicus*) were administered daily oral doses of 0.3mg/kg of Digoxin from the 5<sup>th</sup>- 19<sup>th</sup> day of gestation. The animals were sacrificed at the 20<sup>th</sup> day of gestation. Fetuses were removed from the uterus and evaluated for mortality rate, growth parameters, morphological and skeletal malformation as well as histological study of liver, kidney and brain. Results showed significant reduction in weight gain of pregnant rats and decreased placental weight of pregnant rats treated with Digoxin. Fetal growth retardation during gestational period was recorded. Hematomas and anomalies of limbs were noticed morphologically in the fetuses of the treated group. Fetal skeletal abnormalities were also recorded. These abnormalities included weak ossification of the skull bones roof. Histopathological studies of fetuses during gestation revealed presence of few megakaryoblasts in between hepatocytes in the liver, no histopathological alternations were observed in kidney of the treated group while in the brain tissue edema that was noticed in the meninges following Digoxin administration. Digoxin pretreatment was able to increase the level of lipid peroxidation and it decreased the GSH level. Our findings suggest the need for great caution to handle Digoxin especially during pregnancy.*

**Keywords----** Digoxin, Teratogenicity, Gestation

---

## 1. INTRODUCTION

Teratology is the study of abnormal prenatal development and congenital malformations induced by exogenous chemical or physical agents. Teratogenesis refers to the production of defects in the fetus. A teratogenic agent is responsible for producing such a defect. The term *teratogen* usually is cited in the context of causing anatomical defects in an embryo that was previously differentiating normally. Teratogens include irradiation, chemicals (drugs), and infectious agents. Pregnancy increases the work demands on the heart by increasing blood volume and thereby cardiac output. Therefore, in pregnant patients with organic heart disease, arrhythmias may have significant hemodynamic consequences to the mother with harm to the fetus. Lanoxin is used in the treatment of chronic heart failure and/or atrial fibrillation and flutter (irregular heart rhythms caused by an electrical problem in the upper chambers of the heart). Heart failure is a disease of the heart which develops when the heart muscle cannot pump blood strongly enough to supply all the blood needed throughout the body. Lanoxin contains the active ingredient digoxin, which belongs to a group of medicines called cardiac glycosides. The digoxin crosses the placenta freely and its serum concentrations are similar in the mother and newborn (Rotmenschet *et al.*, 1987). Also digitalis toxicity has been associated with miscarriage and fetal death (Sherman and Locke, 1960).

## 2. MATERIALS AND METHODS

### Animals and treatment:

The present experimental study is carried out on the albino rat (*Rattus norvegicus*). The standard guidelines of the Institutional Animal Care and Use Committee (IACUC) were used in handling animals.

Females of 11-13 weeks old were selected for the present study and vaginal smears prepared every morning and examined under the light microscope according to the method of Snell (1956) for 5 days to select those in the pro-estrus.

Two females with regular estrus cycle were selected in the pro-estrus stage and caged together with one male overnight under controlled environmental conditions of temperature, humidity and light. The first day of gestation was determined by the presence of sperms in the vaginal smear (McClain and Becker, 1975).

A daily record of the weight of the pregnant females was made throughout the whole gestational period. The percentages of abortion were calculated in each group; abortion was determined by the presence of blood drops and sudden drop in the weight of the pregnant females.

**Drug:** The Lanoxin was purchased from Aspen Europe GmbH.

**Duration of drug administration:** 14 days, from the 5<sup>th</sup> day, daily during gestation.

The animals were divided into two groups with twenty animals in each.

**Group A:** Control rats received distilled water orally.

**Group B:** Rats treated with 0.3 mg/kg of body weight of Lanoxin administered orally.

### **Experimental observations:**

On the 19<sup>th</sup> day of gestation, all pregnant rats of groups (A,B) were sacrificed and fetal mortality rate (resorped or still birth) and living fetuses were recorded. Fetal body weight, body length, tail length and external malformation were recorded. Head, neck and limbs were examined.

Fetuses were preserved in 95% ethyl alcohol and were stained with double staining of fetal skeletons for cartilage (Alcian blue) and bone (Alizarin red) according to the method described by Deinzet *et al.*, (1995).

Autopsy samples were taken from liver, kidney and brain of fetuses at the 20<sup>th</sup> day of gestation. They were fixed in 10% formalin, dehydrated through an ascending ethanol series embedded in paraffin wax. Transverse serial sections were cut and stained with haematoxylin and eosin to prepare for histological examination by light microscopy. (Banchroft *et al.*, 1996).

A fraction of the liver and kidney were used to assess oxidative stress markers. Tissue samples were washed in 0.9% saline, and homogenized in 0.2M sodium phosphate pH 7.4 buffers in a homogenizer fitted with a Teflon pestle. The supernatant obtained after centrifugation was used as an enzyme source for biochemical analyses. The fresh supernatant was stored at -20 °C in order to determine reduced glutathione (GSH) according to the procedure of (Beutler *et al.*, 1963), as well as the levels of thiobarbituric acid reactive substances (TBARS) according to the procedure of (Satoh, 1978; Ohkawa, *et al.*, 1979).

### **Statistical analysis:**

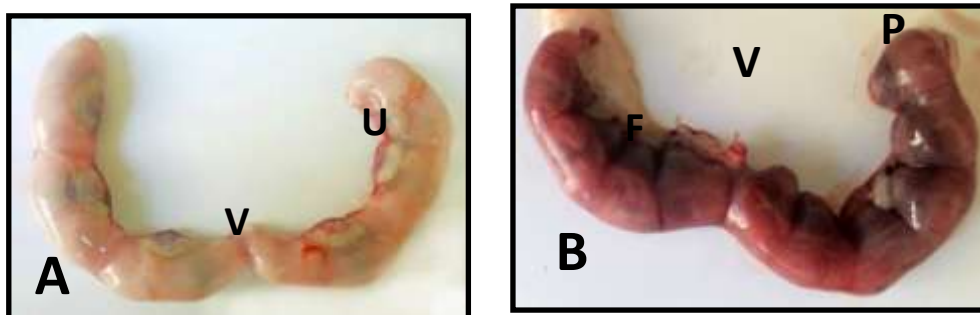
Statistical analysis was performed using the Analysis Of Variance (ANOVA) and Duncan's multiple range tests to determine differences between treatments, means at significance level of 0.05. Standard errors of treatment means were also estimated. All statistics were carried out using Statistical Analysis Systems (SAS) program.

## **3. RESULTS**

### **Morphological studies:**

The pregnant rats treated orally with 0.3 mg/Kg (group B) of digoxin during gestational period (5<sup>th</sup> - 20<sup>th</sup> day) showed no external signs of toxicity. No mortality cases were recorded. There was a significant reduction in maternal weight gain in the treated group when compared with the control group. There was significant ( $P \leq 0.05$ ) reduction in placenta weight of animals that received digoxin. The uterus of control and treated pregnant rats on day 20 of gestation showed normal shape and symmetrical distribution of fetuses in the two uteri (Fig. 1).

**Fig. 1:**



A- A photograph of uterus of control pregnant rat at the 20<sup>th</sup> day of gestation. Showing normal symmetrical distribution of fetuses in the two uteri horns.

B- A Photograph of uterus of pregnant rat treated with 0.3 mg/Kg of digoxin at the 20<sup>th</sup> day of gestation. Showing normal shape and symmetrical distribution of fetuses in the two uteri horns. U= Uterus, V= Vagina, P= Placenta and F= Fetuses.

The morphological examination of the fetuses showed that the digoxin caused growth retardation represented by a decrease in fetal body weight, body length and tail length (Table 1). There was a significant ( $P \leq 0.05$ ) reduction in fetus weight, fetus length and tail length in treated group when compared with the control group (A). Total mortality rate included resorbed fetuses and stillbirth (dead fetuses at birth) and was recorded for both control and treated groups in table 2. The fetus from control animals appeared with normal shape, correct weight and length (Fig. 2), also appeared straight dorsally. The malformations recorded in fetuses from treated group represented in limbs anomalies such as deformed hind limb, kinky tail and contraction in forelimb and also hematoma that detected in various region of fetus like head, face, back and abdominal wall (48.8%).

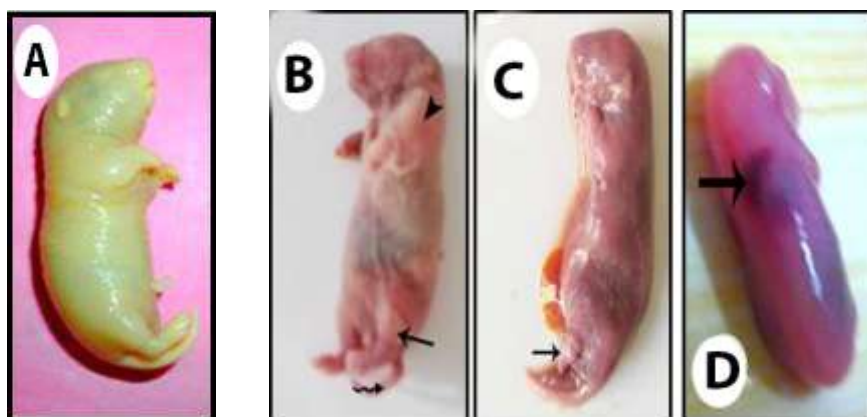
**Table 1:** Showing effect of digoxin on fetus weight, fetus length, tail length, placenta weight and mother weight gain at 20<sup>th</sup> day of gestation. Values are expressed as Mean  $\pm$  SEM. The statistical differences were analyzed by independent samples T test. a=  $P \leq 0.05$  compared with control.

Groups	Total no. of pregnant rats	No. of implantation sites	No. of live fetuses		No. of resorbed fetuses		No. of dead fetuses	
Control (A)	10	67	67	100%	0	0%	0	0%
Treated Groups (5 <sup>th</sup> -20 <sup>th</sup> ) mg/Kg (B)	20	184	172	66.9%	4	2.3%	57	33.1%

**Table 2:** Effect of digoxin on fetal mortality at the 20<sup>th</sup> day of gestation.

Group	Fetus weight (F.WT)	Fetus length (F.L)	Tail length (T.L)	Placenta weight (P.WT)	Mother weight gain (M.WT)
Control (A)	03.63 $\pm$ 0.026	5.19 $\pm$ 0.032	1.6 $\pm$ 0.043	0.6 $\pm$ 0.011	28.50 $\pm$ 2.320
mg/Kg (B)	2.35 $\pm$ 0.098 <sup>a</sup>	3.50 $\pm$ 0.123 <sup>a</sup>	1.28 $\pm$ 0.060 <sup>a</sup>	0.49 $\pm$ 0.023 <sup>a</sup>	12.00 $\pm$ 2.065 <sup>a</sup>

**Fig. 2:**



- A- A Photograph of fetus of control mother at 20<sup>th</sup> day of gestation. Fetus exhibited normal morphology and normal length.
- B-D) Photographs of fetuses of maternally treated with 0.3 mg/Kg of digoxin at 20<sup>th</sup> day of gestation. Showing:
- B- Deformed hind limb (Thin arrow), abnormal fore limb (head arrow) and kinky tail (wavy arrow).
  - C- Shortness in hind limb (Thin arrow).
  - D- Hematoma (Thick arrow).

### **Skeletal anomalies**

In general, the skeleton of the rat fetus at 20<sup>th</sup> day of gestation consist of two main parts; the axial and the appendicular skeleton. The axial skeleton contains the bones of skull, vertebral column, ribs and sternum. The appendicular skeleton comprises the bones of pectoral, pelvic girdles and fore, hind limbs. The skeleton malformations in all groups are represented in Fig. 3.

The skeleton system (axial and appendicular) of fetuses taken from control untreated pregnant rats showed complete ossification of the bones comprises skull. The median dorsal series consists of paired bones; nasal roofing the nasal cavity, frontals, parietals and single median bone. Also upper jaw bones, permaxilla and maxilla were well ossified.

The vertebral column consists of several types of vertebra which is the main structure unit and each one composed of a centrum and a pair of lateral neural arches. There are five types of vertebrae with well ossified centroms and neural arches, cervical (7), thoracic (13), lumbar (6), sacral (4) and caudal (28-30) according to the tail length.

The control rats have 13 pairs of thoracic ribs. Each one consists of well ossified vertebral part and cartilaginous sterna part. The sternal portion of the ribs articulated with the sternum while the last four pairs were freely, has not connection with the sternum, and named the floating ribs.


The sternum composed of 6 well ossified sternbrae. The last one called xiphisternum and connected to small cartilage named xiphoid cartilage.

The pectoral girdle of the control pups consists of well ossified scapula and clavical on the ventral side and suprascapula on the dorsal side which stained blue because it still cartilaginous (Fig. 3). The fore limb composed of well ossified bones, humerus, radius, ulna, carpals, metacarpals and phalanges of five digits 1:2:2:2:2.

The pelvic girdle of untreated pups consists of well ossified ilium, ischium and pubis. The hind limb composed of well ossified bones, femur, tibia, fibula, tarsals, metatarsals and phalanges of five toes 1:2:2:2:2.

On the other hand, fetuses maternally treated with 0.3 mg/Kg of digoxin showed lack of ossification of the skull roof, lack of ossification of metacarpus and phalanges.

**Fig. 3:**



- A) A Photograph of skeletal system of a fetus from control mother at 20<sup>th</sup> day of gestation. Showing well ossified skeleton.
- B&C) Photographs of skeletal system of a fetus from treated mother at 20th day of gestation. Showing:
- B) Incomplete ossification of all cranial bones.
  - C) Lack of ossification of metatarsus and phalanges.

## Histological studies of fetuses:

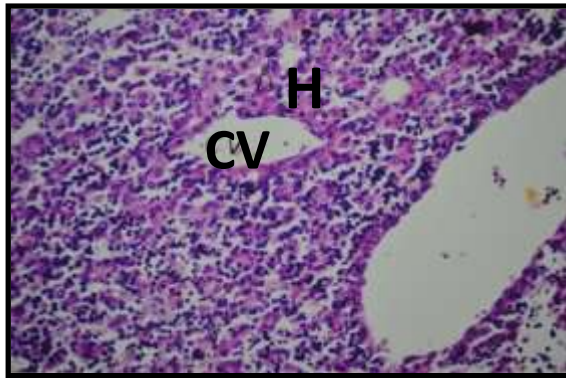
### Liver:

The fetal liver at 20<sup>th</sup> day of pregnancy is covered with a very thin capsule consisting of a single elongated mesothelial cells.

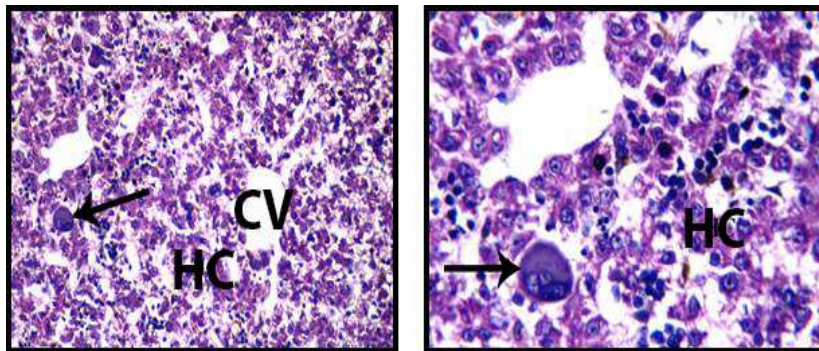
It is formed of homogenous mass of parenchyma cells arranged in hepatic lobules separated by interlobular connective tissue septa which are poorly developed. The hepatic lobules are composed of irregular branched and interconnected hepatic strands of 1-3 cells thick radiating from the central vein to the lobule periphery. The hepatocytes are more or less polygonal in shape with distinct boundaries possessing spherical nuclei. The blood sinusoids are irregularly dilated vessels, lined with a discontinuous layer of endothelial cells intervened by large phagocytic Kupffer's cells. As the liver in the late embryonic stages acts as a hemopoietic organ, a considerable number of different stages of erythroblasts and few megakaryocytes are found in between the hepatic cells (Fig.4)

Examination of the liver of fetuses of treated group B showed numbers of megakaryoblasts were detected in between the hepatocytes (Fig.5).

**Fig. 4:** A Photomicrograph of a section of liver of a fetus from control mother. H&E stain. 100X. Showing normal architecture of the liver tissue. The central vein with its intact endothelial lining (CV). The hepatic lobules that can be only distinguished by their central veins, hepatocytes (H) and blood sinusoids (Si).



**Fig. 5:**



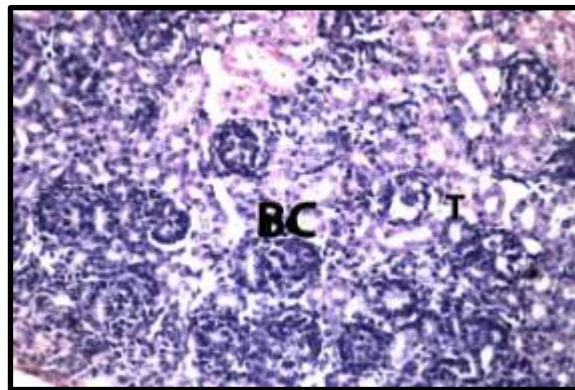
- A) A Photomicrograph of a section of liver of a fetus from treated mother H&E stain. 100X. Showing numbers of megakaryoblasts (arrow) were detected in between the hepatocytes (HC). CV= Central vein.  
B) A Photomicrograph showing the magnification of Fig. 5A. 400X

**Kidney:**

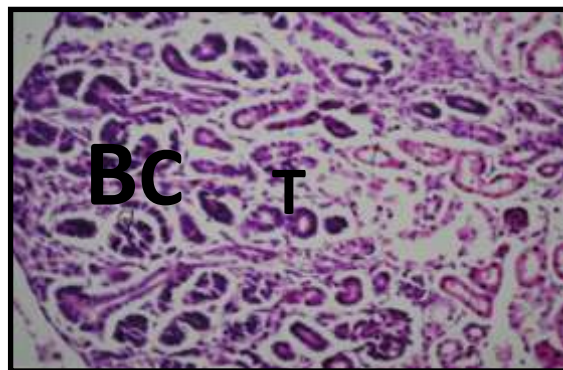
Examination of the kidney of control fetus revealed that it is differentiated into outer cortex and an inner medulla, which is formed of conical pyramids. Each medullary pyramid with the corresponding part of the cortex represents a renal lobe which consists of the uriniferous tubules and stromal tissue. The uriniferous tubule is composed of the nephron which is formed of the Malpighian corpuscle, the proximal convoluted tubule, the descending and the ascending limbs of Henle's loop and the distal convoluted tubule. Each corpuscle consists mainly of a tuft of blood capillaries, or glomerulus and a Bowman's capsule which is a double walled cup formed of two layers, an outer parietal layer and an inner visceral layer separated by a clear, distinct capsular space (urinary space). The proximal convoluted tubules appear rounded, and are lined by a single layer of short columnar cells with indistinct cell boundaries, and spherical nuclei. The distal convoluted tubules are lined with simple cuboidal epithelial cells that possess distinct cell boundaries and a granular cytoplasm, and conspicuous spherical centrally located nuclei (Fig.6).

Examination of the kidney of fetus maternally treated with 0.3 mg/Kg, revealed no histopathological alterations as recorded in Fig. 7.

**Fig. 6:** Photomicrograph of a section of kidney of a fetus from control mother. H&E stain. 100X. Showing a part of the cortical region containing, a glomeruli (G) within Bowman's capsule (BC) and both proximal (x) and distal (D) tubules.



**Fig. 7:** Photomicrographs of a section of kidney of a fetus from treated mother. H&E stain. 100X. Showing no histopathological alterations. BC= Bowman's capsule and T= Tubules.

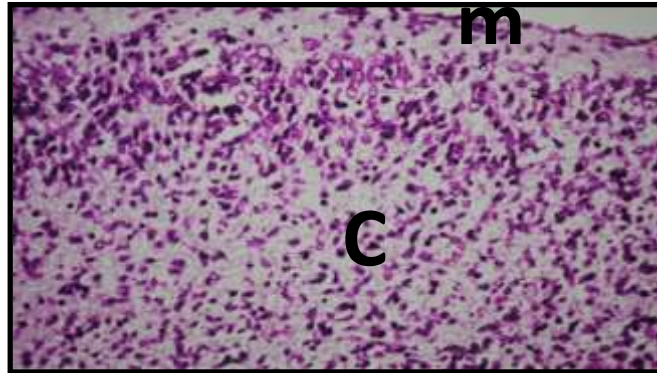


**Brain:**

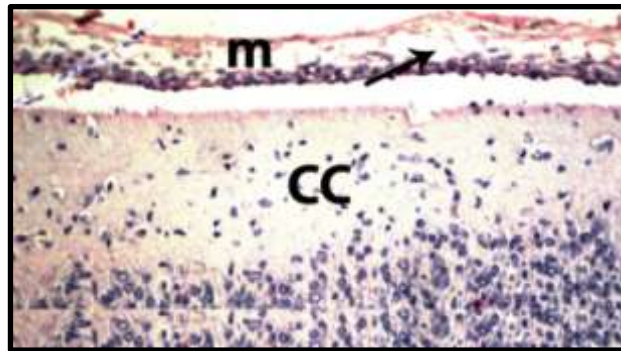
The brain tissues of fetuses from control pregnant rats showed, showed normal features under microscopic observation (Fig.8).

The histological observations of the fetuses brain sections of the rats treated with 0.3 mg/Kg of digoxin demonstrated, oedema that was noticed in the meninges (Fig. 9).

**Fig. 8:** A Photomicrograph of a section of brain of a fetus from control mother. H&E stain. 100X. Showing normal structure of brain tissue, CC= cerebral cortex and m= meninges.



**Fig. 9:** A Photomicrograph of a section of brain of a fetus from treated mother. H&E stain. 100X. Showing oedema (arrow) was noticed in the meninges (m). CC= cerebral cortex.

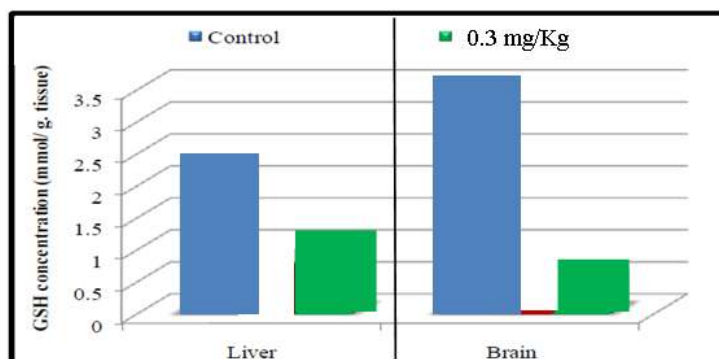


### Oxidative stress investigations during gestation:

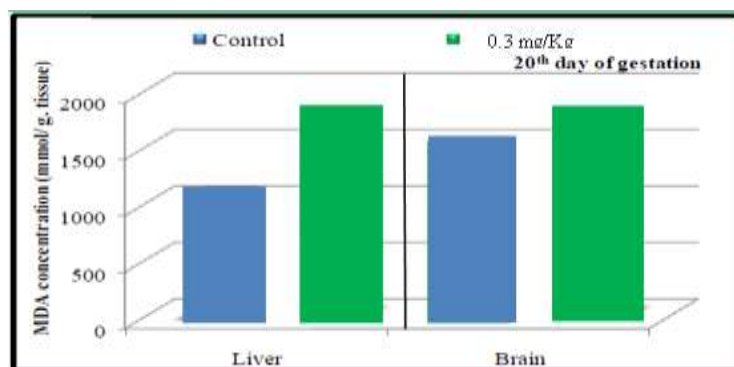
Oxidative stress marker Malondialdehyde (MDA) and antioxidant Glutathione reduced (GSH) in liver and brain of fetuses at the 20<sup>th</sup> day of gestation are observed.

The content of malondialdehyde in liver and brain of fetuses maternally treated with 0.3 mg/kg of Digoxin significant decrease as compared to the control group (Fig.10). Significant decrease in Glutathione reduced (GSH) concentration was found in liver and brain of fetuses maternally treated with 120 mg/kg of Digoxin as compared to the control group (Fig. 11).

**Fig. 10:** A histogram showing effect of Digoxin on the GSH content in liver and brain at the 20<sup>th</sup> day of gestation.



**Fig. 11:** A histogram showing effect of Digoxin on the MDA content in liver and brain at the 20<sup>th</sup> day of gestation.



#### 4. DISCUSSION

The present study is carried out to evaluate the teratogenic potential of Digoxin on the fetuses maternally treated with 0.3 mg/Kg of the used drug during the gestation. However, many of the cardiovascular drugs that are prescribed for a pregnant woman have the potential to cross the placenta and exert a pharmacologic or even teratogenic effect upon the fetus.

Teratology, the study of abnormal prenatal development and congenital malformations induced by exogenous chemical or physical agents, is a growing area of medical research in the quest for the eradication of preventable birth defects. Birth defects are known to occur in huge numbers; roughly 7~10% of all children require extensive medical care to diagnose or treat a birth defect; this compromises the quality of life of millions of people worldwide (O’Rahilly, 2001). Almost all therapeutic agents cross placental barrier and enter fetal circulation. Every agent given during pregnancy therefore has a tendency to produce some sort of structural abnormality in the neonate at birth until proved otherwise (Schlegel *et al.*, 1991). A birth defect or a congenital malformation is a structural abnormality of any type present at birth. It may be macroscopic or microscopic, on the surface or within the body (Moore, 1988). During the past few decades, it has become increasingly evident that human and animal embryos are subjected to the toxic effects of many drugs, such as the use of some antibiotics in the treatment of serious diseases occurring during pregnancy.

There are many physiologic changes that occur during pregnancy, including increased demands on the cardiovascular system. Physiologic changes in the cardiovascular system include peripheral vasodilation resulting in decreased systemic vascular resistance, requiring increased cardiac output. This increase in cardiac output is accomplished by an increase in ventricular end-diastolic volume, wall mass, and contractility, which creates an increase in stroke volume and heart rate. Due to these alterations, pregnant women are placed at higher risk for developing comorbidities such as cardiac arrhythmias that range from benign to life threatening (Burt and Durbridge, 2009 and Joglar and Page, 2014).

An increased incidence of maternal cardiac arrhythmias is observed during pregnancy and they can range from clinically irrelevant isolated premature beats to debilitating supraventricular and ventricular tachycardias (Ferrero *et al.*, 2004).

Digoxin has been assigned to FDA pregnancy category C by the FDA. Animal studies failed to reveal evidence of teratogenicity. There are no controlled data in human pregnancy. Digoxin has been used successfully to treat maternal congestive heart failure and arrhythmias and fetal arrhythmias throughout gestation without reports of fetal harm, however, digoxin should be given during pregnancy only when benefit outweighs risk (Drugs.com).

Negative effects of dioxin action are associated with limited abilities of their bio-degradation along with continuously increasing production and long-term bio-accumulation of those toxins in living organisms. Dioxins penetrate through placenta to fetus indicating indirect toxic effects on offspring of mothers exposed to the action of these toxins (Rosińczuk and Calkosiński, 2015).

In the present study, oral treatment of pregnant rats with Digoxin during the gestation led to a significant reduction in the weight, length and tail length of fetuses. The observed fetal growth retardation may be arising from the direct action of the used drug on embryos and fetal tissues.

The current work revealed that Digoxin treatment induced complete fetal resorption when rats were given 0.3 mg/kg/day of Digoxin at gestational days during organogenesis period.



The present work showed external malformations and skeletal abnormalities. The most repeated anomalies observed were hematoma, fore and hind limb defects, kinky tail, unossified skull bones and absence of ossification of phalanges. Almokalant was administered in the diet during GDs 6-15 in doses of 50, 125, and 300  $\mu\text{mol/kg}$ . No signs of dysfunction were observed in the pregnant dams. A dose dependent embryonic lethality was observed resulting in 100% embryo mortality at the highest tested concentration in agreement with previous studies (**Abrahamsson *et al.*, 1994; Danielsson, 1993**). The mean fetal weight was statistically significantly reduced in the group treated with 125 mg/kg. In the 50 and 125  $\mu\text{mol/kg}$  groups, the incidence of some minor skeletal defects was statistically significantly increased compared with the control group.

Almokalant increased the incidence of embryonic/fetal death, decreased the mean fetal weights and induced external malformations in similarity to what has been shown with other IKr blockers in conventionally designed teratology studies (**Ban *et al.*, 1994; Marks and Terry, 1996; Spence *et al.*, 1994**). Our results regarding almokalant-induced external defects confirm results of **Webster *et al.* (1996)**.

Histopathological findings were observed in the liver and brain of fetuses maternally treated with 0.3 mg/kg of Digoxin from 5th day to 20th day of gestation. Liver showed numbers of mega karyoblasts in between the hepatocytes and brain showed oedema in the meninges.

The exact mechanism that gives rise to hypoxia-related malformations is not fully understood. It has long been known that a reduced oxidation rate will primarily affect organs that are at a rapid proliferation phase at the time, causing discontinuation in development. The hypoxia may result either in organs that consist of sensitive cells dying, becoming retarded or having their differentiation capacity affected in some manner (**Naujoks, 1953**). This could result in an overall embryonic growth retardation that would be more pronounced in the areas with most cell proliferation, such as facial prominences, leading for example to failure of closing the palate (**Bronsky *et al.*, 1986**). A new paper has studied how hypoxia plays a global role in developmental physiology and morphogenesis in rat embryos on GD 9 – 11 (**Chen *et al.*, 1999**). The hypoxia may act as a physiological signal coordinating some group of genes important in development. However, several studies indicate that damage after hypoxic episodes is related to free radicals that are generated during the reoxygenation phase. In adult tissues, generation of free radicals is a well-established mechanism for tissue damage during reoxygenation of the ischemic heart after myocardial infarction, and the central nervous system (CNS) after stroke (**Gutteridge, 1993; McCord, 1993**). The major cause of damage is readmission of oxygen and not the re-establishment of flow (**Kalyanaraman *et al.*, 1995**). Reactive oxygen species (ROS) have also been identified in embryonic tissues after episodes of hypoxia followed by normoxia. **Fantelet *al.*** stated that ROS (superoxide anion radicals generated in mitochondria) were detected in the embryonic tissues corresponding to the distal parts of the digits after two transient 30-minute episodes of hypoxia separated by normoxia in GD 14 rat embryos cultured *in vitro* (**Fantelet *et al.*, 1995**).

Drug-induced oxidative stress is implicated as a mechanism of toxicity in numerous tissues and organ systems, including liver, kidney, ear, and cardiovascular and nervous systems. The extent to which mechanisms of drug-induced oxidative stress have been characterized varies. Oxidative stress affects cellular integrity only when antioxidation is no longer capable of coping with ROS. ROS reacts with the unsaturated fatty acid of cellular or sub cellular membranes. Therefore, they lead to peroxidation of membrane lipids. The oxidative stress caused by different xenobiotics is often estimated by the level of MDA (**Poovalaet *et al.*, 1998; Poovalaet *et al.*, 1999 and Taniguchi *et al.*, 1999**).

In the current study, the fetal tissues from treated group showed higher lipid peroxidation and revealed significant depletion in concentration of GSH than the control tissues.

The almokalant-induced defects are mainly caused by reoxygenation damage after an episode of severe embryonic dysrhythmia, rather than “pure hypoxia”. The mechanism for such embryonic damage is unknown, but may involve generation of free radicals, such as reactive oxygen and nitric oxide species during the reoxygenation phase (**Fantel, 1996; Fantelet *et al.*, 1999**).

**In conclusion:** It is evident that Digoxin is teratogenic and much care must be given to prevent the increased risk if Digoxin is administered during pregnancy.

## 5. REFERENCES

- Abrahamsson, C., Palmer, M., Ljung, B., Duker, G., Bäärnhielm, C., Carlsson, L. and Danielsson, B. (1994): Induction of rhythm abnormalities in the fetal rat heart. A tentative mechanism for the embryotoxic effect of the class III antiarrhythmic agent almokalant. *Cardiovascular Research*. 28, 337-344.
- Allonen, H., Kanto, J. and Ijsalo, E. (1976): The foeto-maternal distribution of
- Ban, Y., Konishi, R., Kawana, K., Nakatsuka, T., Fujii, T. and Manson, J. M. (1994): Embryotoxic effects of L-691,121, a class III antiarrhythmic agent, in rats. *Archives of Toxicology*. 69, 65-71.
- Bancroft, J.D. and Gamble, M. (2002): *Theory and practice of histological techniques*. 5th ed. Churchill Livingstone: London, UK 2002.

- Beutler, E., Duron, O. and Kelly, M.B. (1963): *J. Lab Clin. Med.*, 61: 882.
- Bronsky, P. T., Johnston, M. C., and Sulik, K. K. (1986): Morphogenesis of hypoxia-induced cleft lip in CL/Fr mice. *Journal of Craniofacial Genetics & Developmental Biology - Supplement*. 2, 113-128.
- Burt, C. C. and Durbridge, J. (2009): Management of cardiac disease in pregnancy, *Continuing Education in Anaesthesia, Critical Care and Pain*, 9 (2): 44-47.
- Chen, E.Y., Fujinaga, M. and Giaccia, A.J. (1999): Hypoxic Microenvironment Within an Embryo Induces Apoptosis and Is Essential for Proper Morphological Development. *Teratology*. 60, 215-225.
- Danielsson, B.R. (1993): Developmental Toxicology Preclinical and Clinical Data in Retrospect. Tryckgruppen, Stockholm. Danielsson, B.R. (Malformations and Fetal Hypoxia Induced by Exaggerated Pharmacological Effects. In A. Sundwall, B. R. Danielsson, O. Hagberg, E. Lindgren, P. Sjöberg, and A. Viktor, Eds.), pp. 45-52. Tryckgruppen, Stockholm.
- Deinz, E., Dural, K. and Tuncay, P. (1995): Visualization of the fetal skeletal system by double staining with alizarin red and alcian blue. *Gazi Medical Journal*, 6: 55-58.
- Fantel, A. G. (1996): Reactive oxygen species in developmental toxicity: review and hypothesis. *Teratology*. 53, 196-217.
- Fantel, A. G., Person, R. E., Tumbic, R. W., Nguyen, T. D. and Mackler, B. (1995): Studies of mitochondria in oxidative embryotoxicity. *Teratology*. 52, 190-195.
- Fantel, A. G., Stamps, L. D., Tran, T. T., Mackler, B., Person, R. E., and Nekahi, N. (1999): Role of free radicals in the limb teratogenicity of L-NAME (N(G)-nitro-(L)-arginine methyl ester): a new mechanistic model of vascular disruption. *Teratology*. 60, 151-160.
- Ferrero, S., Colombo, B.M. and Ragni, N. (2003): Maternal arrhythmias during pregnancy. *Arch Gynecol Obstet*. 2004 May; 269 (4):244-53.
- Gutteridge, J. M. (1993). Free radicals in disease processes: a compilation of cause and consequence. *Free Radical Research Communications*. 19, 141-158.
- Joglar, J. A. and Page, R. L. (2014): Management of arrhythmia syndromes during pregnancy, *Current Opinion in Cardiology*. 29 (1): 36-44.
- Jequier, R., Deraedt, F., Plongeron, R. and Vannier, B. (1970): Pharmacology and toxicology of disopyramide [Fr.]. *Minerva Medica.*, 61 (71): 3689-93.
- K. L. Moore, *The Developing Human*, WB Saunders, Philadelphia, Pa, USA, 4th edition, 1988.
- Kalyanaraman, B., Konorev, E. A., Joseph, J., and Baker, J. E. (1995): Is free radical generation an important component of ischemia/reperfusion injury? *Redox Report*. 1, 181-184.
- Marks, T. A. and Terry, R. D. (1996): Developmental toxicity of ibutilide fumarate in rats after oral administration. *Teratology*. 54, 157-164.
- McClain, R. M. and Becker, B.A. (1975): Teratogenicity, foetal toxicity and placental transfer of lead nitrate in rats. *Toxicol. Appl. Pharmacol.*, 931: 72-82.
- McCord, J. M. (1993): Human disease, free radicals, and the oxidant/antioxidant balance. *Clinical Biochemistry*. 26, 351-357.
- Naujoks, H. (1953): Der Einfluss kurzfristigen Sauerstoffmangels auf die Entwicklung des Huhnchens in den ersten fünf Bruttagen. *Beitr. Path. Anat.* 113, 221-252.
- O’Rahilly, R. (2001): *Human Embryology & Teratology*, Wiley-Liss, New York, NY, USA, 3rd edition.
- Ohkawa, H., Ohhishi, W., and Yagi, K. (1979): Assay for lipid peroxides in animal tissues by thiobarbituric acid reaction. *Anal. Biochem.*, 95 (2): 351-358.
- Poovala, V.S., Huang, H. and Salahudeen, A.K. (1999): Role of oxygen metabolites in organophosphate-bidrin-induced renal tubular cytotoxicity. *J. Am. Soc. Neph.*, 10: 1746.
- Poovala, V.S., Kanji V.K., Tachikawa, H. and Salahudeen, A.K. (1998): Role of oxidant stress and antioxidant protection in acephate-induced renal tubular cytotoxicity. *Toxicol. Sci.*, 46: 403.

- Rosińczuk, J., Calkosiński, I. (2015): Assessment of physical traits of rat offspring derived from mothers exposed to dioxin. *Environ Toxicol. Pharmacol.*, 40 (2): 575-80.
- Rotmensch, H.H., Rotmensch, S. and Elkayam, U.(1987): Management of cardiac arrhythmias during pregnancy. *Drugs*. 33: 623–33.
- Satoh, K. (1978): Serum lipid peroxide in cerebrovascular disorders determined by a new colorimetric method. *ClinicaChimicaActa.*, 90(1): 37-43.
- Schlegel, P. N., Chang, T. S. K. and Marshall, F. F. (1991): Antibiotics: potential hazards to male fertility,” *Fertility and Sterility*. 55 (2): 235–242.
- Sherman, J.L. and Locke, R.V.(1960): Transplacental neonatal digitalis intoxication. *Am. J. Cardio.*, 6: 834–7.
- Spence, S. G., Vetter, C. and Hoe, C. M. (1994): Effects of the class III antiarrhythmic, dofetilide (UK-68,798) on the heart rate of midgestation rat embryos, in vitro. *Teratology*. 49, 282-292.
- Taniguchi, M., Yasutake, A., Takedomi, K. and Inoue, K. (1999): Effects of N-nitrosodimethylamine (NDMA) on the oxidative status of rat liver. *Arch. Toxicol.*, 73: 141.
- Webster, W.S., Brown-Woodman, P.D., Snow, M.D. and Danielsson, B.R. (1996): Teratogenic potential of almokalant, dofetilide, and d-sotalol: drugs with potassium channel blocking activity. *Teratology*. 53, 168-175.