

# Left Colic Artery Arising from the Superior Mesenteric Artery: A Case Report

Rekha Bhasin<sup>1</sup>, Sunanda Raina<sup>2</sup>, Sajad Hamid<sup>3</sup>

<sup>1</sup>Department o Anatomy  
Govt. Medical College, Jammu

<sup>2</sup> Department o Anatomy  
Govt. Medical College, Jammu

<sup>3</sup> Department o Anatomy  
SKIMS Medical College, Bemina, Srinagar

---

**ABSTRACT**— *Anatomical variation in the abdominal aorta is common and extremely important. We found a rare variation of the abdominal aorta in a 50 year male cadaver during a routine dissection course. The superior mesenteric artery gives off an artery to descending colon, named left colic artery. The inferior mesenteric artery arises normally from the abdominal aorta and supplied the sigmoid colon and the upper part of the rectum. This variation was rare and it has not been reported previously . Knowledge of the arterial variation in this region is considerable important during abdominal surgery and invasive procedures*

**Keywords**— left colic artery,superior mesenteric artery,middle embryonic tissue,radiological investigations

---

## 1. INTRODUCTION

The **superior mesenteric artery (SMA)** is one of the three non-paired arteries that provide blood to the gut and other abdominal viscera.It is a Single vessel arising anteriorly from abdominal aorta at the level of L1 & Courses anteroinferiorly, behind the neck of pancreas and splenic vein, crossing anterior to the left renal vein. It emerges anterior to the uncinate process of the pancreas and crosses anterior to the third part of duodenum. It then enters the upper portion of the small bowel mesentery and runs along the root of the mesentery downwards to the right .Branches to the jejunum and ileum are given off to the left, and branches to the proximal and mid colon are given off to the right.The SMA terminates at the ileum where it anastomoses with the ileal branch of the ileocolic artery. Some anatomists believe the ileocolic artery is the terminal portion of the SMA and that what many consider the terminal SMA is the last of the ileal branches.The superior mesenteric vein (SMV) should always lie to the right of the SMA, otherwise malrotation should be suspected. The branches of Superior Mesenteric artery are;

- inferior pancreaticoduodenal artery

### *Left-sided*

- jejunal branches
- ileal branches

### *Right-sided*

- ileocolic artery
- right colic artery
- middle colic artery

### 1.1 Inferior pancreaticoduodenal artery

The first branch of the SMA, though it often arises from the first jejunal branch. Anastomoses with branches of the superior pancreaticoduodenal artery (from the gastroduodenal artery). Supplies the head of the pancreas and the duodenum distal to the ampulla of Vater.

### 1.2 Jejunal and ileal branches

Variable in number. Pass in the two layers of the mesentery to the jejunum and ileum. They progressively divide and join in a series of anastomosing arcades. From the arcades, straight arteries (also known as **vasa recta**) pass to the small bowel.

### 1.3 Ileocolic artery

Runs obliquely to the ileocaecal junction. It divides into an **ileal branch** that supplies the terminal ileum and anastomoses with the terminal SMA, and a **colic branch** that supplies the proximal ascending colon and anastomoses with the descending branch of the right colic artery. It also gives off **anterior and posterior caecal arteries**, one or both of which gives off an **appendicular artery**.

### 1.4 Right colic artery

May arise directly from the SMA but often arises from a common trunk with the ileocolic artery or middle colic artery. Courses to the right to the ascending colon. Divides into a **descending branch** that supplies the lower portion of the ascending colon and anastomoses with the colic branch of the ileocolic artery, and an **ascending branch** which supplies the upper portion of the ascending colon and anastomoses at the hepatic flexure with the right branch of the middle colic artery

### 1.5 Middle colic artery

Passes in the layers of the transverse mesocolon to the transverse colon. Divides into a **right branch** that supplies the right portion of the transverse colon and anastomoses at the hepatic flexure with the ascending branch of the right colic artery, and a **left branch** that supplies the left portion of the transverse colon and anastomoses at the splenic flexure with the left colic branch of the IMA.

### 1.6 Marginal artery of Drummond

The terminal branches of the ileocolic, right colic and middle colic arteries - along with the terminal branches of the left colic artery and sigmoid branches of the IMA - form a continuous arterial circle or arcade along the inner border of the colon known as the marginal artery of Drummond. From this marginal artery, straight vessels (also known as **vasa recta**) pass to the colon.

### 1.7 Supply

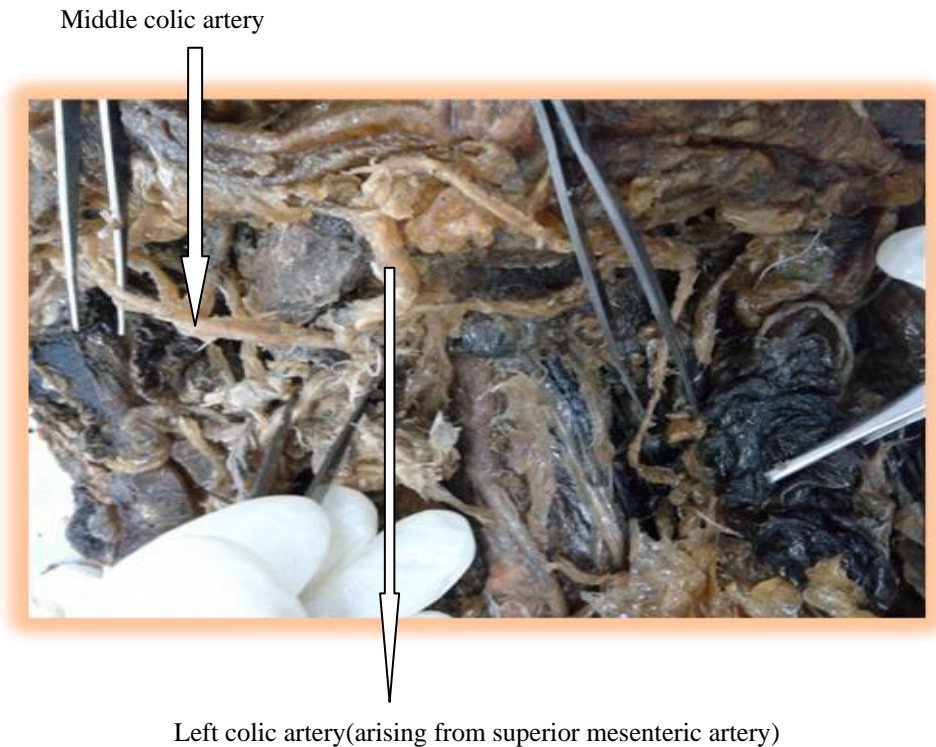
The SMA is the artery to the midgut. It supplies the gut from the ampullary region of the 2<sup>nd</sup> part of the duodenum to the splenic flexure. The inferior pancreaticoduodenal artery also supplies the head of the pancreas. [1]. Numerous variations of the superior mesenteric artery regarding origin, course and branching pattern have been reported in the literature. Ceren Gunenc and C-Cem Denk reported unusual anatomical variation of the superior mesenteric artery and renal artery [2], Oran, Yesildag, Memis et al reported a common splenomesenteric trunk branching into the splenic and superior mesenteric artery by angiographic study [3]. The most common variation of superior mesenteric artery is associated with the origin of a right hepatic artery which arises from the superior mesenteric artery [4], [5]. We report very rare case of origin of left colic artery from the superior mesenteric artery which was not previously reported.

## 2. CASE REPORT

During the routine dissection of 50 yr old male cadaver in the Post –graduate Department of Anatomy, Government Medical College, Jammu. We found that left colic artery was arising from the superior mesenteric artery . which , otherwise, is the first branch of the inferior mesenteric artery .It ascends retroperitoneally, dividing into two branches:

1) **ascending branch:** passes anteriorly to the left kidney, then enters the transverse mesocolon, and passes superiorly to supply the upper part of the descending colon and the distal part of the transverse colon & anastomoses with branches of the middle colic artery

2) **descending branch:** passes inferiorly, supplying the lower part of the descending colon & anastomosis with first sigmoidal artery. Other branches of superior mesenteric artery were having normal course.



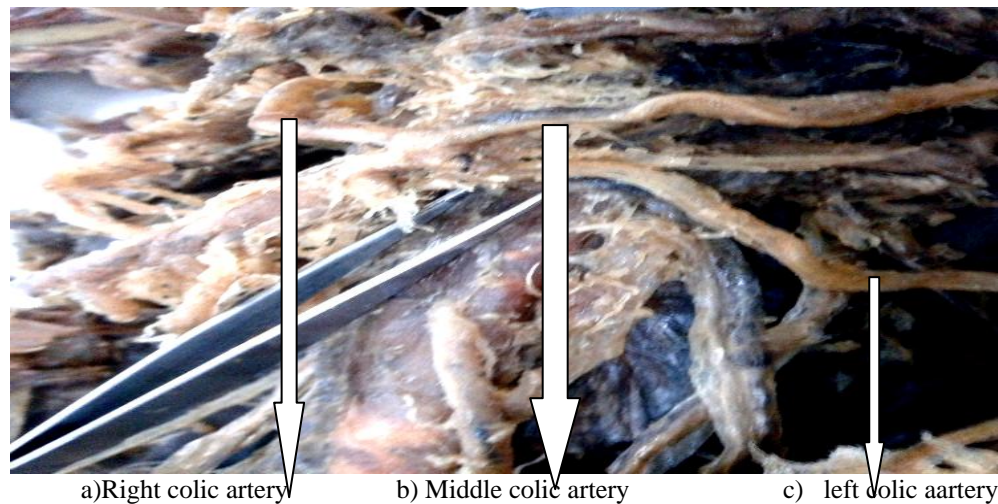
**Figure 1: Showing origin left colic artery from superior mesenteric artery**

### 3. DISCUSSION

Anatomical variations of the visceral arteries, particularly those concerning the superior mesenteric artery are well known in medical literature [3]. The most frequent variations encountered in clinical practice involve a right hepatic artery from superior pancreaticoduodenal artery and left hepatic artery from left gastric artery. However there are some more exceptional anatomical variations that is informative for the surgeon or vascular radiologist, dealing with intraabdominal diseases [3]. The left colic artery has a direct origin (58%) or through a common trunk with left middle colic artery (42%). It can be precocious divided in two (24%). We mention that in this case the left superior colic artery came from superior mesenteric artery.

The development of middle embryonic intestine may be a causal explanation for the origin of superior left colic artery from the superior mesenteric artery

Such type of variation was not reported previously, so it makes the case unique. Anatomical variations of these vessels are due to developmental changes in the ventral splanchnic arteries. During development three groups of collateral arteries arise from the abdominal aorta as somatic intersegmental, lateral splanchnic and ventral splanchnic branches. The ventral splanchnic branches develop initially as a paired vessel, which then coalesce in the median line to form the four roots for the gut, the four roots being connected by the ventral longitudinal anastomoses. In the majority of cases the first three roots coalesce to form the celiac trunk and separate from the fourth root. The future superior mesenteric artery developed from the fourth root, which migrates caudally with the ventral migration of the gut. [3]



**Figure 2: Showing origin of Right colic a(a), Middle colic a.(b) & left colic artery(c) from a common stem**

#### 4. CONCLUSION

Different anatomical variations involving the superior mesenteric artery should be born in mind during both surgical and radiological evaluations. Knowledge of such variations would result in accurate interpretation of disease in diagnostic imaging, as well as the optimum elective procedure in surgical or interventional radiological management [3]. Prior knowledge about the anomalous branching pattern of superior mesenteric artery is essential to successfully accomplish surgical, oncologic or interventional procedures including lymphadenectomy around a hepato-spleno-mesenteric trunk, aortic replacement with reimplantation of trunk, chemoembolization of liver malignancies all of which can potentially create significant morbidity because of the large visceral territory supplied by a single vessel [6].

#### 5. REFERENCES

1. Williams PL, Bannister LH, Berry MM, et al. Gray's anatomy. London; churchill Livingstone; 38<sup>th</sup> ed.pp:1553-1554.
2. Geren GU Nenc, C. Cem Denk. Combined unusual anatomical variations of the superior mesenterric and right renal arteries. Clinical Anatomy. 2006;19:716717.
3. Oran I, Yesildag A, Memis A. Aortic origin of right hepatic artery and superior mesenteric origin of splenic artery: two rare variations demonstrated angiographically. Surg Radiol Anat. 2001 sep; 23(5); 349-352.
4. Judy J. Moon, Coen A. Wildicks, James M. Williams; Right hepatic artery branching off the superior mesenteric artery and its potential implications; international journal of anatomical variations (2009) 2:143-145.
5. Iimura A, Oguchi T, Shibata M, Takahashi T. An anomalous case of the hepatic artery arising from the superior mesenteric artery. Okajimas Folia Anat Jpn. 2007 Aug; 84(2):61-65.
6. Sridhar Varma K, Narendra Pamidi, Venkata R. Vollala. Common celiacomesenteric trunk:a rare anatomic variation. J Vasc Bras. 2009; 8(3): 271-273.